

Report for <b>John Doe</b>	Center Name <b>Dr. Jones</b>	Created <b>9/6/2007</b>	Gender <b>Male</b>	D.O.B. <b>1/8/1928 &gt;&gt;   PDF</b>
-------------------------------	---------------------------------	----------------------------	-----------------------	--

## Carotid Assessment

# A

Good

# B

Satisfactory

# C

Concern


# D

Serious

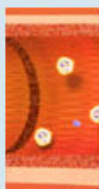
# E

Highest Risk

## Intima-Media Thickness




Normal



Mild



Moderate



Significant



Critical significant

## Plaque Character



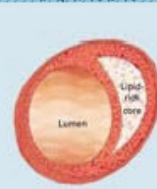
None Observed



Early Buildup



Calcified



Mixed



Soft

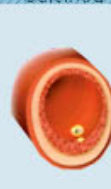## Percent Stenosis



None Observed



Nominal



less than 30%



Between 30% to 50%



Greater than 50%

## Comments...

Comparison scan 06/30/2006, IMT values are stable in both sides. there are some lesions in both sides .

### Carotid Assessment

Your risk of experiencing a heart attack or stroke is graded by zone. The zone assigned is age and gender appropriate to you. The relationship of Intima-Media Thickness (IMT) to atherosclerosis is well established. The results summarized on this page represent the most significant findings of your test measurements. Treatment will be based on your zone in the independent indicators.

### Patient Notification

Prevention and detection of the coronary artery disease and stroke is complex. Normal or thin Carotid IMT does not completely exclude coronary artery disease; it only indicates it is less likely. The results of this test should be interpreted in conjunction with your medical history, known risk factors, other test results and symptoms.

### Plaque Character

Soft plaques are small pools of cholesterol that have collected in the wall of the artery. They are soft as opposed to hard calcified plaques. When soft plaques become inflamed, they can rupture releasing their contents into the blood stream. This event triggers the formation of a blood clot that can block the blood flow through the artery leading to a heart attack or stroke.

### Intima-Media Thickness

The Intima-Media Thickness (IMT) measurement is an accurate way of viewing the effect of atherosclerosis or hardening of the arteries is having on you. The thicker the measurement, the more disease is present. Studies show that in about 90% of the time the disease processes similarly affect the carotid and coronary arteries.

### Percent Stenosis

Stenosis or blockage of the artery occurs when plaques become stabilized due to a build-up of calcified scar tissue. These plaques rarely rupture but when they become large, they can reduce the flow of blood to critical areas. In general, blockages must exceed 75% before they are considered medically important.

Physician Signature

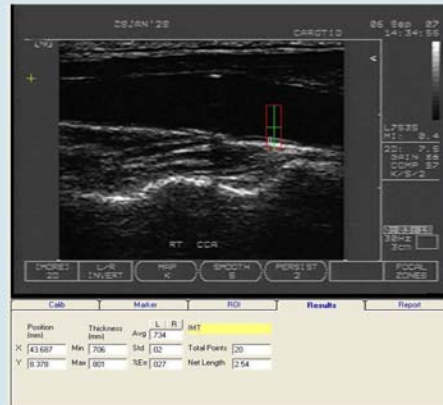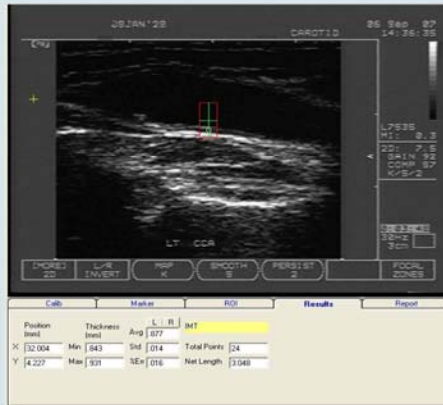Date

Report for <b>John Doe</b>	Center Name <b>Dr. Jones</b>	Created <b>9/6/2007</b>	Gender <b>Male</b>	D.O.B. <b>1/8/1928 &gt;&gt;   PDF</b>
-------------------------------	---------------------------------	----------------------------	-----------------------	--

	LEFT SIDE	RIGHT SIDE
--	-----------	------------

Location	COMMON CAROTID (FAR)	COMMON CAROTID (FAR)
----------	----------------------	----------------------

Your  
Ultrasound  
Image



IMT  
Thickness  
Scale



Mild



Normal

IMT  
Thickness  
Average

0.877mm

0.734mm

## Location

IMT measurements are calculated at the distal common carotid artery (far wall) just before it branches into the internal and external carotid.

## Left/Right Side

Both the right and left carotid arteries are used in our analysis

## Your Ultrasound Image

Included in this report are the ultrasound images that were used to measure your IMT.

## IMT Assessment/Thickness Scale

The age and gender appropriate assessment of the extent of atherosclerosis in your carotid arteries is translated into normal, moderate and significant. It is possible to have normal IMT and yet lesions may be present.

**IMT Thickness Average** Many points along your artery wall are taken into account by our computerized analysis software. The average is then calculated from these measurements.

Physician Signature

Date

Report for <b>John Doe</b>	Center Name <b>Dr. Jones</b>	Created <b>9/6/2007</b>	Gender <b>Male</b>	D.O.B. <b>1/8/1928 &gt;&gt;   PDF</b>
-------------------------------	---------------------------------	----------------------------	-----------------------	--

**Quantity: Multiple**

**LEFT SIDE**

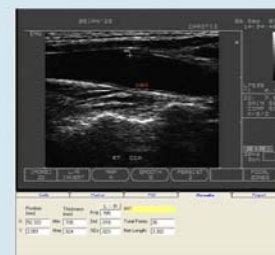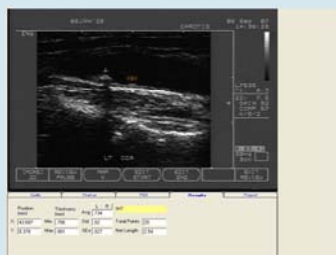
**RIGHT SIDE**

**Location**

**BULB-**

**BULB-**

**Your  
Ultrasound  
Image**

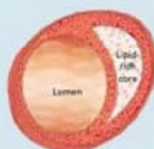

**Density scale**

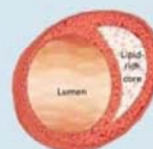
**Location**

**Your  
Ultrasound  
Image**

**Density scale**



**Mixed**



**Mixed**

## Quality

The number of lesions detected by our analysis is translated into a single or multiple indicator.

## Location

The bulb or bifurcation is located at the point where the common carotid artery splits into the internal and external carotid arteries.

## Percent Stenosis

Stenosis is the narrowing of the arteries. Our analysis simplifies the extent of your stenosis in the "greater than 50%" or "less than 50%."

## Your Ultrasound Image

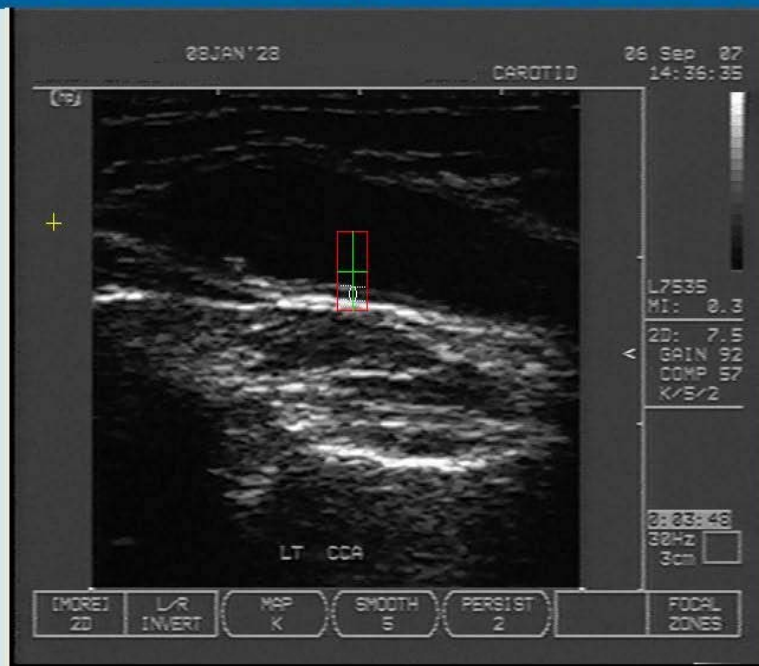
Included in this report are the ultrasound images that were used to analyze the nature of your plaque or lesions.

## Density Assessment Scale

Soft plaque is the most dangerous because it can break loose and travel through the bloodstream. Calcified plaques is hard and mixed is a combination of hard and soft plaque.

Report for	Center Name	Created	Gender	D.O.B.
John Doe	Dr. Jones	9/6/2007	Male	1/8/1928 >>   PDF

## Intima-Media Thickness (IMT) Analysis - Left Side Zoom



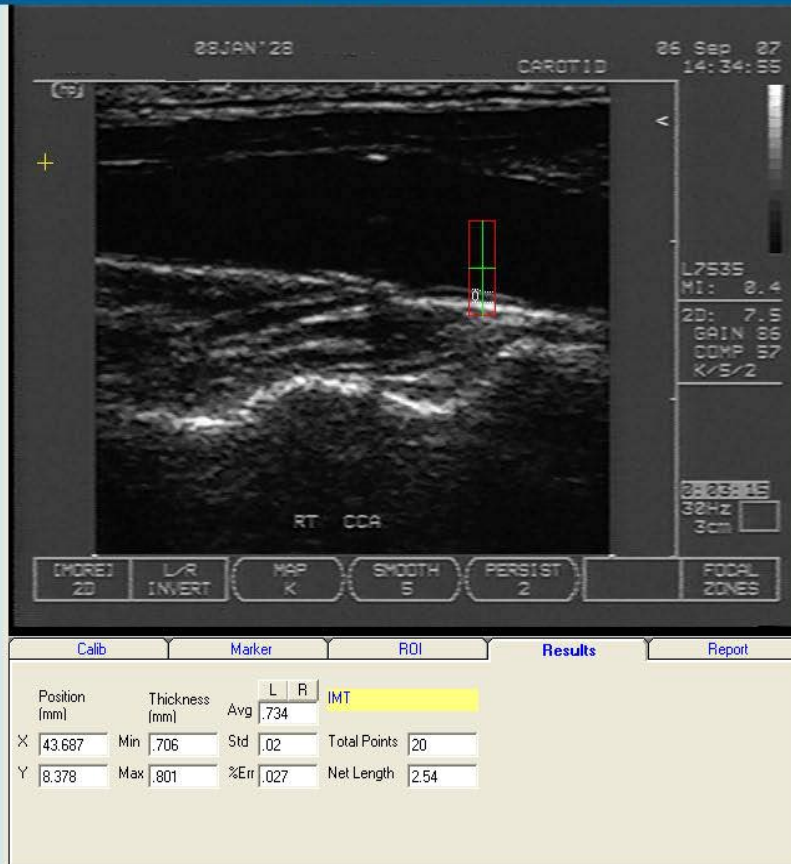Calib		Marker		ROI		Results		Report	
Position (mm)		Thickness (mm)		Avg		L   R		IMT	
X	32.004	Min	.843	Std	.014	Total Points		24	
Y	4.227	Max	.931	%Err	.016	Net Length		3.048	

Physician Signature

Date

Report for	Center Name	Created	Gender	D.O.B.
John Doe	Dr. Jones	9/6/2007	Male	1/8/1928 >>   PDF

## Intima-Media Thickness (IMT) Analysis - Right Side Zoom

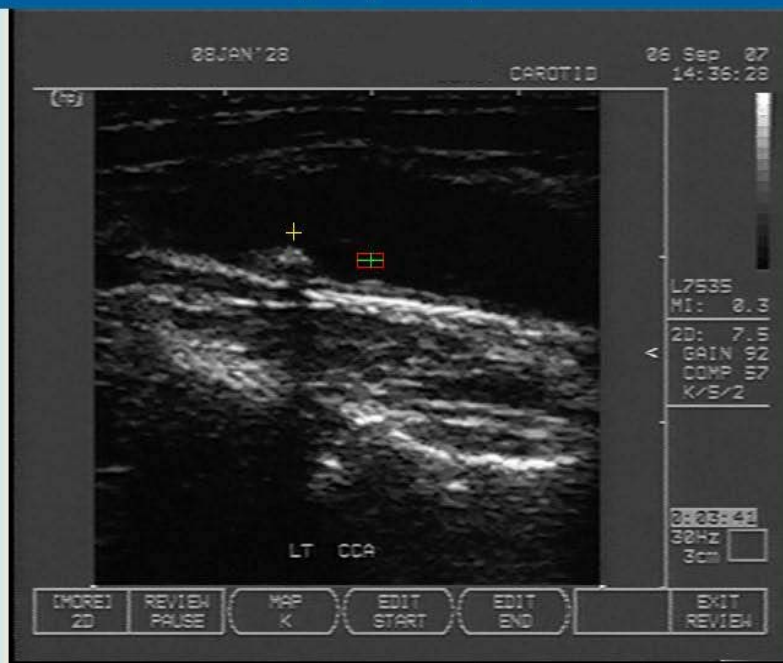

Physician Signature

Date

Report for	Center Name	Created	Gender	D.O.B.
John Doe	Dr. Jones	9/6/2007	Male	1/8/1928 >>   PDF

## Intima-Media Thickness (IMT) Analysis - Left Side Lesion Zoom



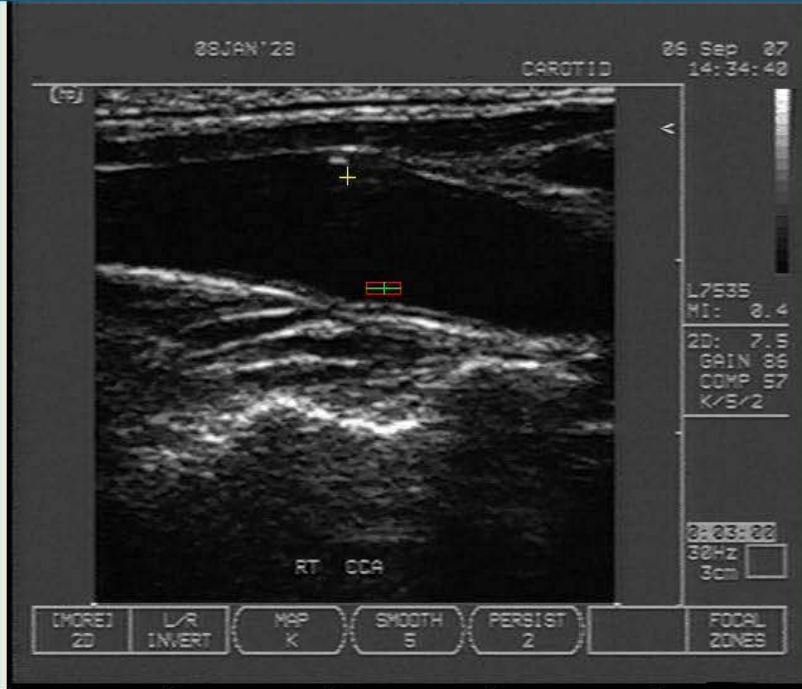
Calib	Marker	ROI	Results	Report
Position (mm)	Thickness (mm)	Avg	L R	IMT
X 43.687	Min .706	Std .02	Total Points 20	
Y 8.378	Max .801	%Err .027	Net Length 2.54	

Physician Signature

Date

Report for	Center Name	Created	Gender	D.O.B.
John Doe	Dr. Jones	9/6/2007	Male	1/8/1928   PDF

## Intima-Media Thickness (IMT) Analysis - Right Side Lesion Zoom



Calib		Marker		ROI		Results	Report
Position (mm)		Thickness (mm)		L	R	IMT	
X	52.322	Min	.726	Std	.018	Total Points	26
Y	2.051	Max	.824	%Err	.023	Net Length	3.302

Physician Signature

Date